

Evaluation of Treat-Eezi Bed Pad

The motivation for carrying out this evaluation is to support the organisation of finding an innovative and cost effective support system for patients with complex chronic pressure ulcers in the community who refused to have pressure relieving equipment at home. It is also to investigate any additional impact to patients' wellbeing.

Two patients were chosen in the community. Objectives and the process of evaluation were explained to patients and family and verbal consent was taken prior to starting of product evaluation.

Mrs X is 95 years old with medical history of aortic stenosis, valve repair (heart), Type 2 DM, Pulmonary oedema, fractured left wrist, hyperthyroidism, high cholesterol, previous fractured pubic rami, poor hearing and has 3 superficial pressure ulcers on the sacrum with blanching surrounding skin, one of the pressure ulcers was sloughy and measures 1cm x 0.5cm, unfortunately patient and next of kin politely refused to have the pressure ulcers photographed but patient has verbalised that the product was comfortable. The sacral pressure ulcers healed after 3 weeks of using the product.

Mr Y is 57 years old with progressing multiple sclerosis, increasing neuropathic pain, lumbosacral radiculopathy, had long term oral antibiotic for osteomyelitis and has chronic category 4 pressure ulcer on the right hip and has been refusing pressure relieving equipment since 2010. Patient had verbalised that Treat-Eezi bed pad is comfortable and patient's next of kin has been continuously repositioning patient whilst in bed. On the second week of using the bed pad there was visually improvement of ulcer bed, although the depth is deeper but is cleaner than the previous week. Every week the evaluation requested patient to rate the level of comfort of the product as either very or fairly comfortable or uncomfortable and patient was consistently giving a good feedback of the bed pad being comfortable to use.

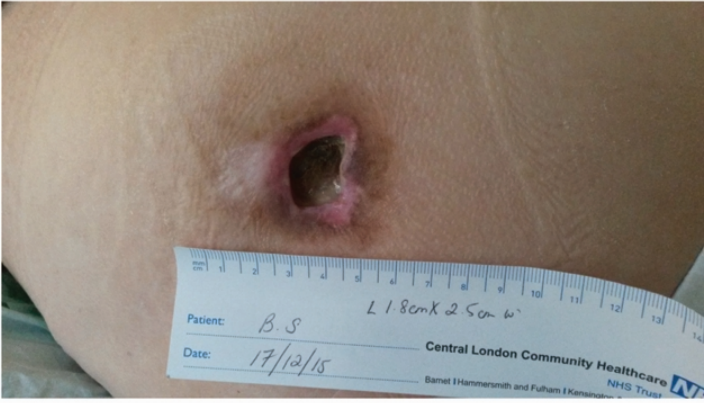On the 6th week of evaluation patient developed a category 3 pressure ulcer on the right shoulder, which prompted Tissue Viability to investigate the incident further. On investigation Tissue Viability found that the new pressure was due to patient's progressing condition and patient has been refusing to be repositioned due to unbearable pain. District nurses have discussed with patient the option of changing the existing Treat-Eezi bed pad to an alternating replacement mattress but patient declined and decided to continue using the bed pad so he can sleep together with his wife on the bed and the mattress they bought together.

Result:

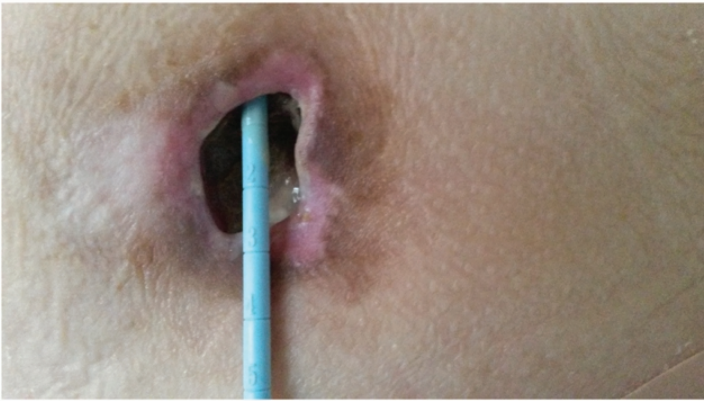The 2 patients' feedback showed a very positive assessment of Treat-Eezi bed pad as both found it comfortable. The evaluation also found that regular repositioning is an important intervention in treating and preventing pressure ulcers together with a good pressure relieving support system. The bed pad has been marketed as an effective system which offers 24-hour protection as it can be easily transferred between bed and chair, unfortunately this has not been fully evaluated as the 2 patients have been confined to their beds for prolonged periods. On the other hand, patients' preference can now be supported, Treat-Eezi bed pad can be considered to those patients with pressure ulcers or at high risk of developing pressure ulcers but consistently refusing to have pressure relieving equipment at home.

Further research could include a randomised controlled trial comparing to hybrid mattress in patients at high risk and to have an accurate costing study to understand better the cost of pressure ulcer in health and social service.

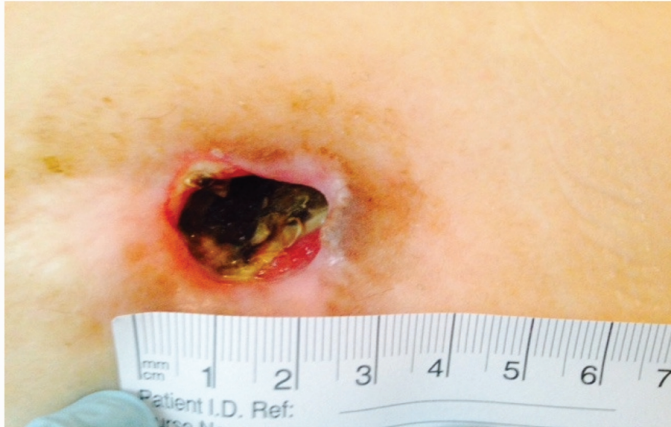Loty Lara BSN RN Tissue Viability Lead
Annalie Canonigo BSN RN Tissue Viability Nurse



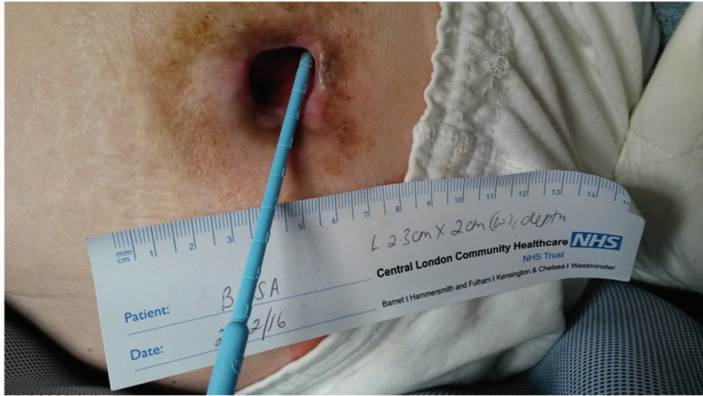
17/12/15- assessed the patient, discussed Treat-Eezi bed pad. Right hip wound. Above picture before Treat-Eezi was used.



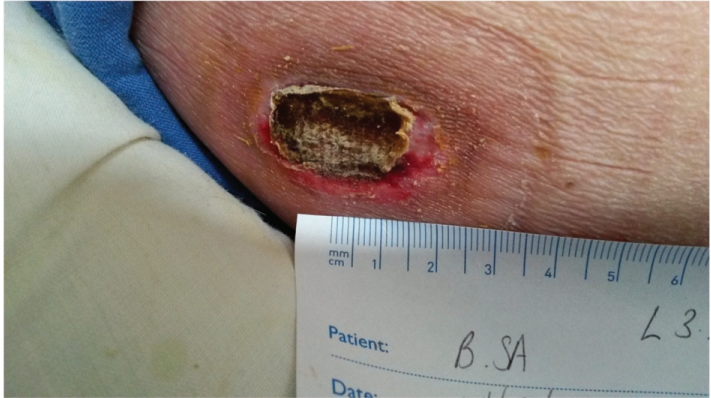Above picture taken 17/12/15, right hip



Above picture taken 27/02/16



24/2/16 after 2 months of using Treat-Eezi bed pad. Treat-Eezi bed pad was delivered 22/12/15. Right hip wound.



Right shoulder wound, 24.2.16